e-ISSN: 3023-6479

AOR

Volume: 3

Issue: 2

Year: 2026

Archives of Ophtalmological Research

MHA
MEDIHEALTH ACADEMY

Archives of
Ophtalmological Research

Editorial Board

EDITOR-IN-CHIEF

Prof. Uğur ACAR
Department of Ophtalmology, Dünyagöz Tunus Hospital, Ankara, Turkiye

ASSOCIATE EDITOR-IN-CHIEF

Prof. Emrullah BEYAZYILDIZ
Department of Ophthalmology, Faculty of Medicine, Medipol University, Ankara, Turkiye

EDITORIAL BOARD

Prof. Ali KAL
Department of Ophthalmology, Konya Practice and Research Center, Başkent University, Konya, Turkiye

Prof. Çağatay ÇAĞLAR
Department of Ophthalmology, Faculty of Medicine, Maltepe University, İstanbul, Turkiye

Prof. Emin KURT
Department of Ophthalmology, Faculty of Medicine, Celal Bayar University, Manisa, Turkiye

Prof. Erkan ÇELİK
Department of Ophthalmology, Dünyagöz Hospital, Sakarya, Turkiye

Prof. Ertuğrul CAN
Department of Ophthalmology, Faculty of Medicine, Ondokuz Mayıs University, Samsun, Turkiye

Prof. Fatih HOROZOĞLU
Department of Ophthalmology, Faculty of Medicine, Erciyes University, Kayseri, Turkiye

Prof. Kenan SÖNMEZ
Department of Ophthalmology, Ankara Etlik City Hospital, Ankara, Turkiye

Prof. Mutlu ACAR
Department of Ophthalmology, Faculty of Medicine, Yüksek İhtisas University, Ankara, Turkiye

Prof. Yusuf YILDIRIM
Department of Ophthalmology, Faculty of Medicine, Medipol University, İstanbul, Turkiye

Prof. Zuleyha YALNIZ AKKAYA
Department of Ophthalmology, Ankara Training and Research Hospital, University of Health Sciences, Ankara, Turkiye

Assoc. Prof. Ahmet KADERLİ
Department of Ophthalmology, Faculty of Medicine, Muğla Sıtkı Koçman University, Muğla, Turkiye

Assoc. Prof. Aslıhan UZUN
Department of Ophthalmology, Faculty of Medicine, Ordu University, Ordu, Turkiye

Assoc. Prof. Burak MERGEN
Department of Ophthalmology, İstanbul Başakşehir Çam and Sakura City Hospital, İstanbul, Turkiye

Assoc. Prof. Burçin KEPEZ YILDIZ
Department of Ophthalmology, İstanbul Başakşehir Çam and Sakura City Hospital, İstanbul, Turkiye

Assoc. Prof. Cafer TANRIVERDİ
Department of Ophthalmology, Faculty of Medicine, Medipol University, İstanbul, Turkiye

Assoc. Prof. Cemal ÖZSAYGILI
Department of Ophthalmology, Kayseri City Hospital, Kayseri, Turkiye

Assoc. Prof. Duygu GÜLMEZ SEVİM
Department of Ophthalmology, Faculty of Medicine, Erciyes University, Kayseri, Turkiye

Assoc. Prof. Duygu YALINBAŞ YETER
Department of Ophthalmology, Ankara Bilkent City Hospital, Ankara, Turkiye

Archives of
Ophtalmological Research

Editorial Board

Assoc. Prof. Esra ŞAHLI
Department of Ophthalmology, Faculty of Medicine, Ankara University, Ankara, Turkiye

Assoc. Prof. Esra VURAL
Department of Ophthalmology, İstanbul Başakşehir Çam and Sakura City Hospital, İstanbul, Turkiye

Assoc. Prof. Fatmagül YILMAZ ÇINAR
Department of Ophthalmology, Ankara Training and Research Hospital, University of Health Sciences, Ankara, Turkiye

Assoc. Prof. Havva ERDOĞAN KALDIRIM
Department of Ophthalmology, İstanbul Başakşehir Çam and Sakura City Hospital, İstanbul, Turkiye

Assoc. Prof. Kemal ÖZÜLKEN
Department of Ophthalmology, Faculty of Medicine, TOBB ETU University, Ankara, Turkiye

Assoc. Prof. Muammer ÖZÇİMEN
Department of Ophthalmology, Konya Training and Research Hospital, Konya, Turkiye

Assoc. Prof. Muhammed BATUR
Department of Ophthalmology, Faculty of Medicine, Van Yüzüncü Yıl University, Van, Turkiye

Assoc. Prof. Muhammed Mustafa KURT
Department of Ophthalmology, Faculty of Medicine, Samsun University, Samsun, Turkiye

Assoc. Prof. Murat KARAPAPAK
Department of Ophthalmology, İstanbul Başakşehir Çam and Sakura City Hospital, İstanbul, Turkiye

Assoc. Prof. Ömer Ersin MUZ
Department of Ophthalmology, Eskişehir City Hospital, Eskişehir, Turkiye

Assoc. Prof. Pınar BİNGÖL KIZILTUNÇ
Department of Ophthalmology, Faculty of Medicine, Ankara University, Ankara, Turkiye

Assoc. Prof. Raşit KILIÇ
Department of Ophthalmology, Faculty of Medicine, Tokat Gaziosmanpaşa University, Tokat, Turkiye

Assoc. Prof. Sabiha GÜNGÖR KOBAT
Department of Ophtalmology, Faculty of Medicine, Fırat University, Elazığ, Turkiye

Assoc. Prof. Şenay AŞIK NACAROĞLU
Department of Ophthalmology, Faculty of Medicine, Medipol University, İstanbul, Turkiye

Assoc. Prof. Veysel CANKURTARAN
Department of Ophthalmology, Dünyagöz Hospital, Ankara, Turkiye

Asst. Prof. Ayşe BOZKURT OFLAZ
Department of Ophthalmology, Faculty of Medicine, Selçuk University, Konya, Turkiye

Asst. Prof. Dilara ÖZKOYUNCU KOCABAŞ
Department of Ophthalmology, Faculty of Medicine, TOBB ETU University, Ankara, Turkiye

Asst. Prof. Mehmet ARGUN
Department of Ophthalmology, Faculty of Medicine, Süleyman Demirel University, Isparta, Turkiye

Asst. Prof. Uğur TUNÇ
Department of Ophthalmology, Faculty of Medicine, Medipol University, İstanbul, Turkiye

Editorial Board

ENGLISH LANGUAGE EDITOR

Spec. Mohammad Bilal ALSAVAF, MD
Department of Otorhinolaryngology, Faculty of Medicine, Ohio State University, OH, USA

STATISTICS EDITOR

Assist. Prof. Maruf GÖĞEBAKAN
Department of Maritime Business and Administration, Maritime Faculty, Onyedi Eylül University, Balıkesir, Turkiye

LAYOUT EDITOR

Şerife KUTLU
Engineer, MediHealth Academy Publishing, Ankara, Turkiye

Archives of
Ophtalmological Research

Contents

Volume: 3 Issue: 2 Year: 2026

ORIGINAL ARTICLE

Evaluation of the efficacy of blue-light monofocal intraocular lenses in cataract surgery: a single-center observational study **23-27**
Şener H, Karameşe V, Sönmez HK, Ünlü M, Horozoğlu F, Gülmez Sevim D.

CASE REPORTS

Ophthalmologic evaluation and management of early adult-onset classic myotonic dystrophy type 1: a case report **28-30**
Canleblebici M.

Acute angle closure following repeated periocular Botulinum toxin injection for blepharospasm: a case report **31-33**
Ölmez Y, Dursun E.

Co-existence of multiple sclerosis and vitiligo in a patient with epithelial map-dot-fingerprint dystrophy **34-37**
Eker S, Bozkurt B, Ekmekçi H, Eren F.

LETTER TO THE EDITOR

Comments on "Impact of phacoemulsification on choroidal and ganglion cell complex thickness assessed by spectral-domain optical coherence tomography" **38-39**
Güçlü İ.

Archives of
Ophtalmological Research

Original Article

DOI: 10.51271/AOR-0049

Evaluation of the efficacy of blue-light monofocal intraocular lenses in cataract surgery: a single-center observational study

Hidayet Şener*, **Veli Karameşe**, **Hatice Kübra Sönmez**, **Metin Ünlü**, **Fatih Horozoğlu**, **Duygu Gülmez Sevim**

Department of Ophthalmology, Faculty of Medicine, Erciyes University, Kayseri, Turkiye

Cite this article: Şener H, Karameşe V, Sönmez HK, Ünlü M, Horozoğlu F, Gülmez Sevim D. Evaluation of the efficacy of blue-light monofocal intraocular lenses in cataract surgery: a single-center observational study. *Arch Ophthalmol Res.* 2026;3(2):23-27. doi:10.51271/AOR-0049

Received: 13/03/2026 ◆ **Accepted:** 23/04/2026 ◆ **Published:** 30/06/2026

ABSTRACT

Aims: Blue-light filtering intraocular lenses (IOLs) have been introduced to reduce retinal exposure to short-wavelength light, potentially protecting against macular damage and enhancing visual function. This study aims to evaluate the clinical efficacy of the Acriva BB UD 613 blue-light filtering monofocal intraocular lens (IOL) in patients undergoing cataract surgery, focusing on visual acuity, contrast sensitivity, and postoperative outcomes.

Methods: This was a prospective, single-center observational study conducted at Erciyes University. Patients aged 50 years or older who underwent phacoemulsification with implantation of the Acriva BB UD 613 IOL were included. The sample size was determined based on the clinical volume of eligible patients meeting the inclusion criteria during the study period. Visual acuity, contrast sensitivity, and refractive outcomes were assessed at multiple postoperative time points (0-3 days, 7-14 days, 1-2 months, and 4-6 months). Statistical analyses included Wilcoxon signed ranks test and repeated measures analysis for longitudinal comparisons.

Results: A total of 64 patients (mean age: 66.18±10.27 years) were included. Uncorrected visual acuity (UCVA) and best-corrected visual acuity (BCVA) significantly improved postoperatively ($p<0.05$). Contrast sensitivity remained stable at all follow-up visits, with no significant changes in color perception. No major complications were observed, and posterior capsular opacification incidence was low.

Conclusion: In this single-center observational study, the Acriva BB UD 613 blue-light filtering monofocal IOL demonstrated significant improvements in visual acuity and maintained contrast sensitivity, which are consistent with expected outcomes following routine crystalline lens extraction. These findings support its use as a safe and effective option for cataract surgery. Further long-term studies are needed to assess its impact on retinal health and potential protective effects against macular degeneration.

Keywords: Acriva BB UD 613, blue-light filtering intraocular lens, cataract surgery, contrast sensitivity, macular protection, phacoemulsification

INTRODUCTION

The macula, a specialized region of the retina, plays a critical role in central vision and color perception. Spanning approximately 5 mm in diameter, it contains carotenoid pigments like lutein and zeaxanthin, which naturally filter short-wavelength light such as blue and violet, protecting the retina from potential phototoxic damage.[1] Maintaining macular health is essential for clear vision, as diseases affecting this region, such as age-related macular degeneration (AMD), can cause significant vision loss.[2] AMD is a leading cause of blindness in older adults, with its prevalence rising sharply after the age of 50. While risk factors like genetics and smoking are well-established, the potential role of cumulative blue-light exposure in AMD progression remains a subject of scientific investigation.[3]

Blue-light filtering intraocular lenses (IOLs) have been introduced to reduce retinal exposure to short-wavelength light, aiming to mitigate phototoxic risks and enhance visual performance. These lenses, which incorporate yellow chromophores, selectively block blue light while maintaining overall light transmission.[4] They are particularly relevant in cataract surgery, where the natural crystalline lens is replaced with an artificial intraocular lens (IOL). While blue-light filtering IOLs offer potential benefits, such as protecting against macular damage and improving contrast sensitivity,

***Corresponding Author:** Hidayet Şener, hidayetsener00@gmail.com

This work is licensed under a Creative Commons Attribution 4.0 International License.

concerns persist about their impact on circadian rhythms and color vision.[5]

The primary objective of this study is to evaluate the clinical efficacy of the Acriva BB UD 613 monofocal IOL in a real-world setting. The research focuses on patients who have undergone cataract removal via phacoemulsification and subsequently received this specific lens implant. By assessing critical outcomes, such as visual acuity and contrast sensitivity, the study aims to provide comprehensive evidence of the lens's performance in routine clinical practice, ultimately contributing to the enhancement of cataract patient care and surgical outcomes.

METHODS

Ehics

This was a prospective, single-center observational study designed to evaluate the safety and efficacy of the Acriva BB UD 613 monofocal IOL in patients undergoing cataract surgery. The study complied with the Declaration of Helsinki and was approved by the institutional ethics committee. All participants provided informed consent prior to inclusion in the study. It has been approved by the Erciyes University Clinical Researches Ethics Committee (Date: 19.03.2025, Decision No: 2025/150).

Study Population

The study included patients aged 50 years or older who underwent cataract removal through phacoemulsification. The sample size (n=64) was determined based on the total volume of eligible patients who met the specific inclusion and exclusion criteria during the designated study recruitment period. Eligibility criteria required the primary implantation of the Acriva BB UD 613 monofocal intraocular lens in one or both eyes. Participants were limited to those with cataracts graded below grade 4, as defined by CTCAE v5.0. Additional inclusion criteria included an axial length ranging between 21.0 mm and 26.0 mm and corneal astigmatism of less than 1.0 diopters for non-toric lenses.

Patients were excluded if they had a history of prior ocular surgeries or systemic or ocular conditions likely to impact surgical outcomes, such as advanced diabetes with retinopathy, amblyopia, or glaucoma. Individuals with irregular astigmatism, such as keratoconus, or those experiencing significant surgical complications, including vitreous loss, were also excluded.

Surgical Procedure

All cataract surgeries were performed by (two) experinced ophthalmic surgeons (MU vs FH) using the AMO Signature Whitestar Pro Phacoemulsification System. This advanced system incorporates elliptical ultrasound technology and precise fluidics to ensure efficient lens removal with minimal ocular disruption. The phacoemulsification process was carried out under balanced infusion and aspiration flow rates to maintain a stable anterior chamber. Surgery was initiated with a 2.8 mm clear corneal incision along the steep axis, creating a short tunnel for entry. After lens removal, the Acriva BB UD 613 intraocular lens was implanted through a corneal incision using a acrijetfly injection system, enabling accurate placement within the capsular bag with minimal tissue manipulation.

Technical Specifications of Acriva BB UD 613 IOL

The Acriva BB UD 613 intraocular lens is a monofocal, biconvex, and aspheric lens made from hydrophobic acrylic material with a water content of 25%. It has an optic diameter of 6.0 mm and an overall length of 13.0 mm. The lens features an asphericity value of -0.1 µm, which enhances visual performance by reducing spherical aberrations. It is designed to block ultraviolet and harmful short-wavelength visible light, with a spectral transmittance cut-off of <10% at 370 nm. The lens has a Refractive Index of 1.46 (measured at 546 nm) and offers a wide dioptric power range from 0.00 D to 32.00 D in 0.5 D increments. With an MTF value exceeding 0.6 at 20.00 D and 100 lp/mm, and an Abbe number of 58, the lens minimizes chromatic aberration while maintaining high image quality. Additionally, the yellow chromophore integrated into the lens selectively filters blue light, reducing retinal phototoxicity and supporting optimal visual clarity.

Outcome Measures

The primary outcomes of the study included best-corrected visual acuity (BCVA) and contrast sensitivity performance. These metrics were used to evaluate the efficacy of the Acriva BB UD 613 intraocular lens in improving postoperative visual function.

Secondary outcome included the incidence of posterior capsular opacification (PCO), which was monitored to assess the lens's long-term safety and stability.

Data Collection

Data were collected during scheduled preoperative and postoperative visits at 1-3 days, 7-10 days, 30-60 days, and 120-180 days. Evaluated parameters included uncorrected and corrected visual acuity, refractive error, and contrast sensitivity under photopic and mesopic conditions. Additionally, biomicroscopic evaluations were conducted to assess the position of the implanted lens and document any adverse effects.

Statistical Analysis

The collected data were analyzed using both descriptive and inferential statistical methods. Continuous variables were expressed as mean±standard deviation, while categorical variables were presented as frequencies and percentages. Non-parametric tests, such as the Wilcoxon signed ranks test, were used to compare preoperative and postoperative outcomes for non-normally distributed variables. For repeated measures across multiple time points, the Friedman test was employed to assess statistical significance in longitudinal changes. Analysis of variance (ANOVA) or Kruskal-Wallis tests were applied where appropriate to compare differences between groups, and pairwise comparisons were conducted with Bonferroni adjustments to control for multiple testing. Statistical significance was set at $p<0.05$ for all tests. Data were analyzed using SPSS version 21 software.

RESULTS

A total of 64 patients were evaluated, with a mean age of 66.18±10.27 years (range: 46-88). The majority of participants were female (68.8%, 44 females, and 20 males). The biometric parameters of the eyes are listed in Table 1. The mean axial length was 23.53±1.67 mm (range: 21.16-25.99 mm),

and the anterior chamber depth averaged 3.08±0.39 mm (range: 2.05-3.88 mm). The white-to-white (WTW) corneal diameter measured 11.74±0.41 mm (range: 10.80-12.63 mm). Additionally, the lens thickness (LT) was 4.15±0.39 mm (range: 2.84-5.12 mm), while the mean corneal thickness (pachymetry) was 538.52±47.58 µm (range: 465-682 µm).

Table 1. Biometric descriptives data of study population

Variables	Values
Age	66.18±10.27 (46-88)
Axial length	23.53±1.67 (21.16-25.99)
Anterior chamber depth	3.08±0.39 (2.05-3.88)
White to white	11.74±0.41 (10.80-12.63)
Lens thickness	4.15±0.39 (2.84-5.12)
Corneal thickness	538.52±47.58 (465.00-682.00)

The refractive error outcomes are listed in Table 2 and were evaluated across five time points; preoperatively, 0-3 days, 7-14 days, 1-2 months, and 4-6 months postoperatively. For spherical refractive error (S), the mean value improved from -1.75±4.50 preoperatively to 0.00±0.93 at 0-3 days, 0.05±0.90 at 7-14 days, 0.02±0.89 at 1-2 months, and remained stable at 0.02±0.90 at 4-6 months. Although there was a trend toward improvement, the changes were not statistically significant at any time point (p>0.05). The cylindrical refractive error (C) remained relatively consistent, with a mean of -1.23±0.89 preoperatively and -1.33±0.88 at 0-3 days, -1.38±0.74 at 7-14 days, -1.32±0.76 at 1-2 months, and -1.30±0.78 at 4-6 months. Again, no significant differences were observed over time (p>0.05). For axis (AX), the preoperative mean was 100.2±41.9, which showed slight fluctuations postoperatively, including 106.98±46.7 at 0-3 days, 105.48±47.0 at 7-14 days, 100.0±45.5 at 1-2 months, and 101.7±46.2 at 4-6 months. These variations were also not statistically significant (p>0.05).

at 7-14 days, 14.26±2.86 at 1-2 months, and 14.86±1.57 at 4-6 months. No statistically significant differences were observed between these postoperative time points (p>0.05).

Table 3. Intraocular pressure outcomes

Time point	Mean±SD	p-value (preop vs time point)	Comparison with next time point	p-value
Preoperative	13.37±2.34	-	0-3 days	0.05
0-3 days	14.85±2.60	0.05	7-14 days	0.39
7-14 days	14.33±2.74	0.38	1-2 months	0.39
1-2 months	14.26±2.86	0.70	4-6 months	0.39
4-6 months	14.86±1.57	-	-	-

SD: Standard deviation

The uncorrected visual acuity (UCVA) outcomes are listed in Table 4 nd were evaluated at five time points; preoperatively, 0-3 days, 7-14 days, 1-2 months, and 4-6 months postoperatively. The mean UCVA significantly improved from 0.20±0.12 (range: 0.00-0.40) preoperatively to 0.63±0.52 (range: 0.05-1.00) at 0-3 days, 0.76±0.23 (range: 0.10-1.00) at 7-14 days, 0.78±0.23 (range: 0.10-1.00) at 1-2 months, and 0.81±0.22 (range: 0.10-1.00) at 4-6 months. Statistically significant differences were observed between the preoperative and all postoperative time points (p<0.05), highlighting the efficacy of the intervention. While the UCVA showed significant improvement between 0-3 days and subsequent time points (7-14 days, 1-2 months, and 4-6 months, p<0.05), no significant differences were noted between 7-14 days, 1-2 months, and 4-6 months (p>0.05). These results indicate that the most substantial gains in UCVA occur within the first two weeks postoperatively, with visual outcomes stabilizing thereafter.

The BCVA outcomes are listed in Table 5 and were evaluated at five time points; preoperatively, 0-3 days, 7-14 days, 1-2 months, and 4-6 months postoperatively. The mean BCVA significantly improved from 0.31±0.19 (range: 0.05-1.00) preoperatively to 0.82±0.23 (range: 0.10-1.00) at 0-3 days, 0.85±0.22 (range: 0.10-1.00) at 7-14 days, 0.88±0.17 (range: 0.20-1.00) at 1-2 months, and 0.91±0.18 (range: 0.10-1.00)

Table 2. Refractive error outcomes

Parameter	Time point	Mean±SD	p-value (preop vs time point)	Comparison with next time point	p-value
S	Preoperative	-1.75±4.50	-	0-3 days	0.15
	0-3 days	0.00±0.93	0.15	7-14 days	0.64
	7-14 days	0.05±0.90	0.15	1-2 months	0.64
	1-2 months	0.02±0.89	0.15	4-6 months	0.64
	4-6 months	0.02±0.90	0.15	-	-
C	Preoperative	-1.23±0.89	-	0-3 days	0.15
	0-3 days	-1.33±0.88	0.15	7-14 days	0.66
	7-14 days	-1.38±0.74	0.15	1-2 months	0.13
	1-2 months	-1.32±0.76	0.15	4-6 months	0.51
	4-6 months	-1.30±0.78	0.15	-	-
AX	Preoperative	100.2±41.9	-	0-3 days	0.44
	0-3 days	106.98±46.7	0.44	7-14 days	0.43
	7-14 days	105.48±47.0	0.26	1-2 months	0.43
	1-2 months	100.0±45.5	0.23	4-6 months	0.43
	4-6 months	101.7±46.2	0.65	-	-

SD: Standard deviation, S: Sphere, C: Cylinder, AX: Axis

The intraocular pressure outcomes are listed in Table 3 were evaluated at five time points: preoperatively, 0-3 days, 7-14 days, 1-2 months, and 4-6 months postoperatively. The mean value increased from 13.37±2.34 preoperatively to 14.85±2.60 at 0-3 days (p=0.05). Subsequently, the mean values were 14.33±2.74

Table 4. UCVA outcomes

Time point	Mean±SD (min-max)	p-value (preop vs time point)	Comparison with next time point	p-value
Preoperative	0.20±0.11 (0.00-0.40)	-	0-3 days	<0.01
0-3 days	0.63±0.52 (0.05-1.00)	0.001	7-14 days	<0.01
7-14 days	0.76±0.22 (0.10-1.00)	<0.001	1-2 months	0.93
1-2 months	0.78±0.23 (0.10-1.00)	<0.001	4-6 months	0.11
4-6 months	0.81±0.22 (0.10-1.00)	<0.001	-	-

UCVA: Uncorrected visual acuity, SD: Standard deviation, Min: Minimum, Max: Maximum

Table 5. BCVA outcomes

Time point	Mean±SD (min-max)	p-value (preop vs time point)	Comparison with next time point	p-value
Preoperative	0.31±0.19 (0.05-1.00)	-	0-3 days	<0.01
0-3 days	0.82±0.23 (0.10-1.00)	<0.01	7-14 days	0.37
7-14 days	0.85±0.22 (0.10-1.00)	<0.01	1-2 months	0.52
1-2 months	0.88±0.17 (0.20-1.00)	<0.01	4-6 months	0.18
4-6 months	0.91±0.18 (0.10-1.00)	<0.01	-	-

BCVA: Best-corrected visual acuity, SD: Standard deviation, Min: Minimum, Max: Maximum

at 4-6 months. Statistically significant differences were observed between the preoperative and all postoperative time points ($p<0.05$), highlighting the intervention's effectiveness. Although BCVA continued to improve significantly between 0-3 days and 4-6 months ($p<0.05$), no statistically significant differences were found between 7-14 days, 1-2 months, and 4-6 months ($p>0.05$). These findings suggest that the most substantial improvement in BCVA occurs during the early postoperative period, particularly within the first two weeks, with outcomes stabilizing thereafter.

Contrast sensitivity outcomes are listed in Table 6. The contrast sensitivity outcomes were evaluated under various conditions, including photopic and mesopic settings, with and without glare, at spatial frequencies of 3, 6, 12, and 18 cycles per degree (cpd). The measurements were taken preoperatively and at 1-2 months and 4-6 months postoperatively. Overall, contrast sensitivity remained stable over time across all tested conditions, with minor fluctuations that were not clinically significant. The findings suggest that postoperative contrast sensitivity function is well maintained across different spatial frequencies and lighting conditions.

Table 6. Contrast sensitivity outcomes

Contrast sensitivity	cpd	1-2 months (mean±SD)	4-6 months (mean±SD)
Photopic binocular	3	1.52±0.30	1.51±0.30
Photopic with glare	3	1.49±0.27	1.49±0.27
Mesopic binocular	3	1.45±0.29	1.45±0.28
Mesopic with glare	3	1.47±0.28	1.46±0.29
Photopic binocular	6	1.66±0.27	1.67±0.30
Photopic with glare	6	1.7±0.26	1.71±0.27
Mesopic binocular	6	1.66±0.30	1.66±0.28
Mesopic with glare	6	1.73±0.24	1.71±0.28
Photopic binocular	12	1.37±0.32	1.38±0.32
Photopic with glare	12	1.42±0.30	1.45±0.33
Mesopic binocular	12	1.37±0.31	1.38±0.30
Mesopic with glare	12	1.42±0.30	1.42±0.31
Photopic binocular	18	0.96±0.30	0.98±0.36
Photopic with glare	18	1.02±0.30	1.03±0.34
Mesopic binocular	18	0.95±0.33	0.97±0.34
Mesopic with glare	18	0.98±0.32	0.99±0.36

cpd: Cycles per degree, SD: Standard deviation

DISCUSSION

Blue light-filtering IOLs are designed to reduce the transmission of potentially harmful blue and ultraviolet (UV) light to the retina.[6,7] The primary rationale for their development is to mitigate retinal damage and decrease the risk of AMD.[8] Short-wavelength light is suggested to contribute to retinal phototoxicity and the progression of AMD; thus, blue light-filtering IOLs are hypothesized to protect retinal cells by reducing this exposure.[9] Consequently, these lenses may aid in preserving macular health and function, potentially lowering the risk of AMD development.[10,11]

Current literature indicates no significant differences in BCVA and contrast sensitivity between eyes implanted with blue light-filtering IOLs and those with only UV-filtering IOLs.[12-14] Additionally, while blue light-filtering IOLs may induce a slight shift in color perception, this change has been reported as not statistically significant.[13] Clinically, patients generally do not perceive a noticeable difference in color vision between blue light-filtering and non-blue light-filtering IOLs.[13]

The primary findings of our study indicate that these lenses enhance visual acuity, maintain contrast sensitivity, and provide a safe option for implantation. Following the implantation of Acriva BB UD 613 lenses, both BCVA and UCVA significantly improved. These results align with previous research suggesting that blue light-filtering IOLs do not have a significant adverse effect on BCVA or contrast sensitivity.[12]

Studies investigating the impact of blue light-filtering IOLs on sleep quality have found no significant effect.[15] Pittsburgh Sleep Quality Index (PSQI) scores did not differ significantly between individuals with blue light-filtering IOLs and those with conventional IOLs.[16] While UV-blocking IOLs have been associated with a slight improvement in sleep quality in the early postoperative period, this difference was not statistically significant in the long term.[17] Overall, the current body of evidence suggests that blue light-filtering IOLs do not have a meaningful impact on sleep quality.

Limitations

This study has several limitations that should be considered when interpreting the findings. First, the single-center

design may limit the generalizability of the results to broader populations with diverse demographic and clinical characteristics. Second, the follow-up period of six months, while sufficient to assess early visual outcomes, may not capture long-term complications such as PCO and its impact on visual function, and possible long-term retinal effects. Additionally, the absence of a control group, such as patients implanted with a UV-only IOL, makes it difficult to determine whether the observed outcomes are specifically attributable to the blue-light filtering feature of the lens or simply the result of standard cataract removal.

CONCLUSION

In this single-center observational study, the Acriva BB UD 613 blue-light filtering monofocal intraocular lens demonstrated significant improvements in uncorrected and BCVA following cataract surgery, which is consistent with expected outcomes following routine crystalline lens extraction. Contrast sensitivity was maintained postoperatively, and no significant adverse effects were observed. These findings suggest that blue-light filtering IOLs are a safe and effective option for implantation in cataract patients.

ETHICAL DECLARATIONS

Ethics Committee Approval

This study was approved by the Erciyes University Clinical Researches Ethics Committee (Date: 19.03.2025, Decision No: 2025/150).

Informed Consent

Written informed consent was obtained from all individual participants prior to their inclusion in the study. Participants were fully informed about the study's aims, procedures, potential risks and benefits, and their rights-including the right to withdraw at any time without consequence. All participants voluntarily signed a written informed consent form.

Peer Review Process

This manuscript was subject to external peer review.

Conflict of Interest

The authors declare no conflicts of interest related to this study.

Financial Disclosure

This study received financial support from VSY Biotechnology, which provided the Acriva BB UD 613 intraocular lenses used in the research. The sponsor had no involvement in the study design, data collection, analysis, interpretation, or the decision to publish the manuscript.

Author Contributions

Concept: HŞ, VK, HKS, MÜ, FH, DGS; Design: HŞ, VK, HKS, MÜ, FH, DGS; Control: HŞ, VK, HKS, MÜ, FH, DGS; Resources: HŞ, VK, HKS, MÜ, FH, DGS; Materials: HŞ, VK, HKS, MÜ, FH, DGS; Data Collection and/or Processing: HŞ, VK, HKS, MÜ, FH, DGS; Analysis and/or Interpretation: HŞ, VK, HKS, MÜ, FH, DGS; Literature Review: HŞ, VK, HKS, MÜ, FH, DGS; Writing the Article: HŞ, VK, HKS, MÜ, FH, DGS; Critical Review: HŞ, VK, HKS, MÜ, FH, DGS.

REFERENCES

1. Junghans A, Sies H, Stahl W. Macular pigments lutein and zeaxanthin as blue light filters studied in liposomes. *Arch Biochem Biophys*. 2001; 391(2):160-164. doi:10.1006/abbi.2001.2411
2. Carpentier S, Knaus M, Suh M. Associations between lutein, zeaxanthin, and age-related macular degeneration: an overview. *Crit Rev Food Sci Nutr*. 2009;49(4):313-326. doi:10.1080/10408390802066979
3. Loane E, Nolan JM, O'Donovan O, Bhosale P, Bernstein PS, Beatty S. Transport and retinal capture of lutein and zeaxanthin with reference to age-related macular degeneration. *Surv Ophthalmol*. 2008;53(1):68-81. doi:10.1016/j.survophthal.2007.10.008
4. Loskutova E, Nolan J, Howard A, Beatty S. Macular pigment and its contribution to vision. Nutrients. 2013;5(6):1962-1969. doi:10.3390/nu5061962
5. Nolan JM, O'Reilly P, Loughman J, et al. Augmentation of macular pigment following implantation of blue light-filtering intraocular lenses at the time of cataract surgery. *Invest Ophthalmol Vis Sci*. 2009;50(10): 4777-4785. doi:10.1167/iovs.08-3277
6. Blackmore-Wright S, Eperjesi F. Blue-light filtering intraocular lenses. *Eur Ophthalmic Rev*. 2012;6:104. doi:10.17925/eor.2012.06.02.104
7. Cionni RJ. Blue-Light-Filtering Intraocular Lenses. In: Fine IH, Packer M, Hoffman RS. (eds) Refractive Lens Surgery. Springer; 2005.
8. Busija L, Keller PR. Blue-light filtering intraocular lenses (IOLs) for protecting macular health. *Cochrane Database Syst Rev*. 2018:1-25. doi:10.1002/14651858.CD011977
9. Cuthbertson FM, Peirson SN, Wulff K, Foster RG, Downes SM. Blue light-filtering intraocular lenses: review of potential benefits and side effects. *J Cataract Refract Surg*. 2009;35(7):1281-1297. doi:10.1016/j.jcrs.2009.04.017
10. Achiron A, Elbaz U, Hecht I, et al. The effect of blue-light filtering intraocular lenses on the development and progression of neovascular age-related macular degeneration. *Ophthalmology*. 2021;128(3):410-416. doi:10.1016/j.ophtha.2020.07.039
11. Downie LE, Wormald R, Evans, J, et al. Analysis of a systematic review about blue light–filtering intraocular lenses for retinal protection: understanding the limitations of the evidence. *JAMA Ophthalmology*. 2020;137(6):694-697. doi:10.1001/jamaophthalmol.2019.0019
12. Lavric A, Pompe MT. Do blue-light filtering intraocular lenses affect visual function? *Optom Vis Sci*. 2014;91(11):1348-1354. doi:10.1097/OPX.0000000000000390
13. Wirtitsch MG, Schmidinger G, Prskavec M, et al. Influence of blue-light-filtering intraocular lenses on color perception and contrast acuity. *Ophthalmology*. 2009;116(1):39-45. doi:10.1016/j.ophtha.2008.08.035
14. Popov I, Jurenova D, Valaskova J, et al. Effect of blue light filtering ıntraocular lenses on visual perception. *Medicina (Kaunas)*. 2021;57(6): 559. doi:10.3390/medicina57060559
15. Landers J, Tamblyn D, Perriam D. Effect of a blue-light-blocking intraocular lens on the quality of sleep. *J Cataract Refract Surg*. 2009; 35(1):83-88. doi:10.1016/j.jcrs.2008.10.015
16. Alexander I, Cuthbertson F, Ratnarajan G, et al. Impact of cataract surgery on sleep in patients receiving either ultraviolet-blocking or blue-filtering intraocular lens implants. *Invest Ophthalmol Vis Sci*. 2014;55(8):4999-5004. doi:10.1167/iovs.14-14054
17. Lee TM, Loh EW, Kuo TC, Tam KW, Lee HC, Wu D. Effects of ultraviolet and blue-light filtering on sleep: a meta-analysis of controlled trials and studies on cataract patients. *Eye (Lond)*. 2021;35(6):1629-1636. doi:10.1038/s41433-020-01132-2

Archives of
Ophtalmological Research

Case Report

DOI: 10.51271/AOR-0050

Ophthalmologic evaluation and management of early adult-onset classic myotonic dystrophy type 1: a case report

Mehmet Canleblebici
Department of Ophthalmology, Kayseri State Hospital, Kayseri, Turkiye

Cite this article: Canleblebici M. Ophthalmologic evaluation and management of early adult-onset classic myotonic dystrophy type 1: a case report. *Arch Ophthalmol Res.* 2026;3(2):28-30. doi:10.51271/AOR-0050

Received: 23/05/2026 ◆ **Accepted:** 24/06/2026 ◆ **Published:** 30/06/2026

ABSTRACT

Myotonic dystrophy type 1 (DM1) is an autosomal dominant disease with variable age of onset and clinical severity, involving not only the musculoskeletal system but also multiple organs including the eyes, heart, lungs, and endocrine system. A 28-year-old woman with a known diagnosis of DM1 presented with blurred vision. Ophthalmologic examination revealed bilateral blepharoptosis, hatchet-face appearance, nuclear sclerosis, and early Christmas-tree cataract with polychromatic refractile opacities. Fundus examination demonstrated hyperpigmented macular changes, while optical coherence tomography showed retinal pigment epithelial irregularities, reticular pigmentary abnormalities, mild epiretinal membrane, and increased macular thickness. Family history revealed affected father and severe congenital involvement in deceased male siblings, suggesting anticipation. Systemic evaluation showed mild intellectual disability and muscle involvement without current cardiac arrhythmia. The patient was referred for multidisciplinary follow-up including neurology, cardiology, pulmonology, and internal medicine. This case highlights the importance of ophthalmologic evaluation in recognizing early DM1 and its multisystemic involvement.
Keywords: Myotonic dystrophy 1, cataract, epiretinal membrane, blepharoptosis, retinal pigment epithelium

INTRODUCTION

Myotonic dystrophy type 1 (DM1) is an autosomal dominant (AD), multisystemic neuromuscular disorder that may involve not only skeletal muscles but also the eye, heart, respiratory system, endocrine system, and central nervous system.[1] Ocular findings, particularly early-onset cataract, blepharoptosis, and retinal abnormalities, may be among the important clinical clues for diagnosis and follow-up.[2,3] Therefore, ophthalmologists may play an important role in recognizing the disease and managing patients for appropriate multidisciplinary evaluation. In this case report, we aimed to draw attention and present its subtle ocular manifestations which may be missed in early adult-onset classic DM1.

CASE

A 28-year-old female patient who had diagnosis of DM1 9-years earlier presented with complaints of blurred vision. Her father also had the same diagnosis and had died 6 years earlier at the age of 55 due to pulmonary infection and multiple organ failure (Figure 1). Her mother and 21-year-old sister had no known systemic disease. One of her brothers had been stillborn approximately 40 years ago, while another brother had died at the age of 8 months approximately 38 years earlier. A possible pedigree and allelic inheritance showed in Figure 2. Review of the medical records demonstrated gait disturbance, difficulty with fine motor skills, and mild intellectual disability (the IQ test score was 64). She was using salbutamol inhaler and montelukast tablets for asthma. The patient was under regular follow-up by the neurology department without any specific treatment.

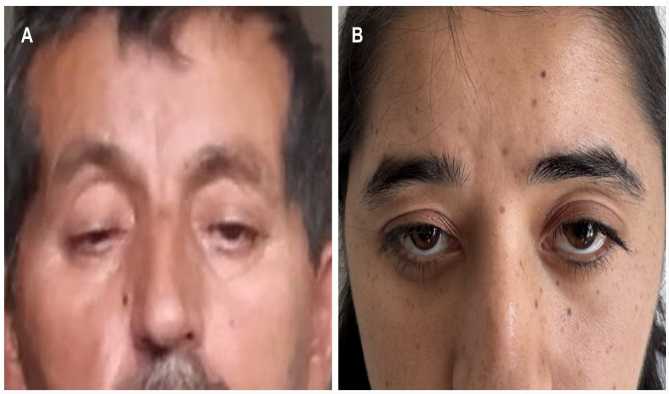

Figure 1. Hatchet face appearance. (A) The patient's deceased father demonstrating severe bilateral blepharoptosis, facial muscle weakness, and elongated facial appearance. (B) Our patient showing milder bilateral blepharoptosis and characteristic hatchet-face appearance

Corresponding Author: Mehmet Canleblebici, mehmetcl@hotmail.com

This work is licensed under a Creative Commons Attribution 4.0 International License.

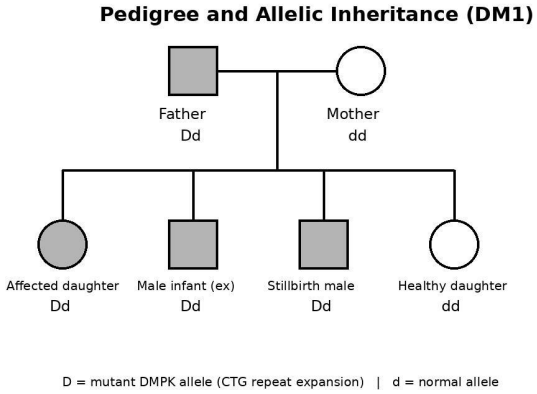

Figure 2. A possible pedigree and allelic inheritance pattern of the patient's family with myotonic dystrophy type 1

The best-corrected visual acuity with her old spectacles had six years ago, measured as -2.50×175° in the right eye and -2.50×173° in the left eye, was 0.1 bilaterally. Bilateral blepharoptosis was observed, with marginal reflex distance-1 (MRD-1) values of 2 mm in the right eye and 3 mm in the left eye with hatchet-face appearance. Palpebral fissure heights were 13 mm bilaterally. Levator function was 11 mm in the right eye and 12 mm in the left eye, and margin crease distance was 9 mm bilaterally (Figure 1). Ocular movements, and pupillary light reflexes were normal. Cycloplegic autorefraction values were -2.50-2.00×20° and -1.75-2.50×10° in the right and left eyes, with these values visual acuity improved to 0.7 in the right eye and 0.8 in the left eye. Intraocular pressure measured by applanation tonometry was 12 mmHg bilaterally. Dilated anterior segment examination showed bilateral grade-2 nuclear sclerosis with early Christmas-tree cataract (Figure 3).

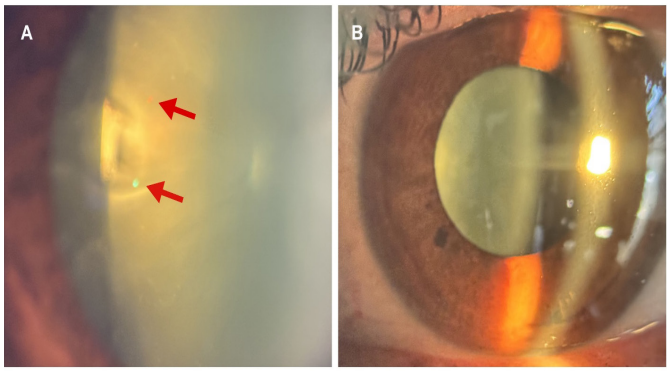

Figure 3. Anterior segment findings of the patient, bilateral increase in nuclear sclerosis grade observed. (A) High magnification of slit-lamp image of the right eye demonstrating polychromatic refractile opacities consistent with early Christmas-tree cataract (red arrows). (B) The left eye

Fundus examination revealed hyperpigmented areas and mild surface reflex changes in the right macula, and hyperpigmentary changes in the left macula (Figure 4). The optic discs appeared cupless but otherwise normal. Macular optical coherence tomography (OCT) demonstrated a mild epiretinal membrane (ERM) in the left eye, along with reticular pigmentary abnormalities and retinal pigment epithelial (RPE) irregularity in each eye with increased thickness of macula (Figure 5). Additional imaging with fundus autofluorescence and fluorescein angiography was recommended for further evaluation; however, these modalities were not available at our hospital, and the patient and her family declined referral.

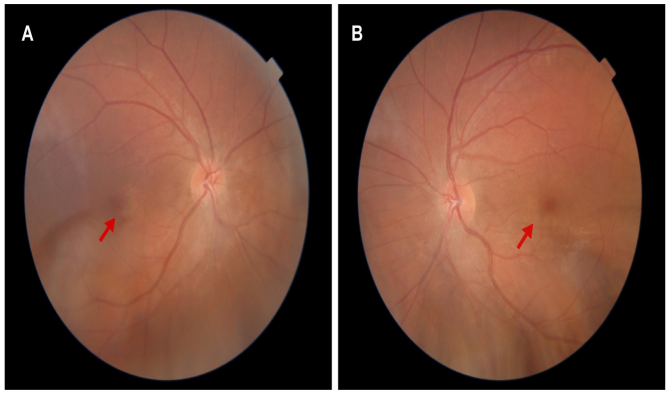

Figure 4. Fundus photographs of the patient showing focal hyperpigmentary alterations in the macular region (red arrow). (A) The right eye (B) The left eye

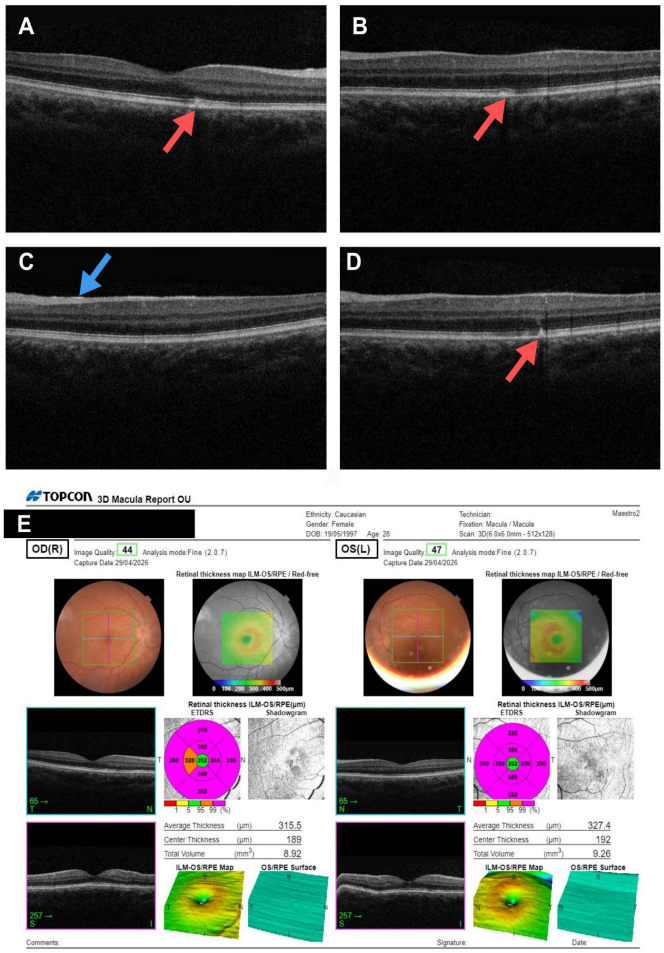

Figure 5. Macular optical coherence tomography findings of the patient. (A, B, and D) Focal retinal pigment epithelium irregularities and reticular pigmentary abnormalities in the macular region (red arrows). (C) Mild epiretinal membrane in the left eye (blue arrow). (E) Bilateral retinal thickness maps demonstrating increased macular thickness

The patient scheduled for ophthalmologic follow-up per 6 months. Since the blepharoptosis was mild and did not obstruct the visual axis, conservative follow-up was recommended. She was informed about the possible systemic implications of her disease, and consultations were requested. No hormonal abnormality was detected. Cardiology consultation revealed no arrhythmia. Echocardiography showed an ejection fraction of 60%, mild grade 1-2 mitral regurgitation, mild tricuspid regurgitation, and a pulmonary arterial pressure of 30 mmHg. The patient was placed under follow-up by these departments. Written informed consent was obtained from the patient and her family for publication and images.

DISCUSSION

Steinert's disease, also known as DM1, is caused by a CTG trinucleotide repeat in 3' untranslated region of the DMPK gene, and presents AD.[1] While the number of repeats ranges from 5 to 34 in normal individuals, repeats above 50 are associated with the disease. As the number of repeats increases, the age of onset decreases, and the clinical severity increases.[3,4]

The mild form is usually characterized by cataracts and mild myotonia, while the classic form as observed in our patient and her father, is predominantly characterized by distal muscle weakness, myotonia, cataracts, and cardiac conduction disorders.[5] As observed in the patient's deceased male siblings, the congenital form is characterized by hypotonia, widespread muscle weakness, respiratory failure, and intrauterine or infantile death.[3]

Muscle involvement usually begins with distal muscle weakness, and gait disturbances, foot drop, and loss of fine motor skills may develop.[6] Myogenic blepharoptosis and a typical facial appearance like our patient, may occur due to involvement of the facial and levator muscles. These findings had developed during adolescence in our patient.

In most patients, Christmas-tree cataracts, seen as iridescent refractile opacities on slit-lamp examination, develop over time. Cataracts usually become apparent in the 30s and 40s and may need early cataract surgery.[2] The spherical change the patient had experienced over six years may be related to refractive variability and lens-related changes due to nuclear sclerosis. Ophthalmoplegia and retinal changes may also be seen in some patients.[3]

Abed et al.[7] evaluated retinal involvement in patients with DM1, and butterfly and reticular pigmentary abnormalities accompanied by drusenoid deposits and focal disruption of the photoreceptor and RPE layers, epiretinal membrane were observed more frequently in DM1 patients compared to healthy controls. The authors also suggested that these retinal alterations may reflect premature retinal aging associated with DM1. ERM may be observed in up to approximately 50% of patients with DM1.[8] Akan et al.[9] reported increased central macular thickness in DM1 patients without statistical significance, however Abed et al.[7] and Vasilijevic et al.[8] found a statistically significant increase in central macular thickness such as our patient. In these patients, visual impairment may also result from retinal abnormalities, not solely from cataract.

Cardiac conduction disorders, arrhythmias, and sudden cardiac death may occur in DM1. Therefore, annual ECG and Holter monitoring are recommended.[10] Respiratory system involvement is associated with progressive restrictive lung disease and increased susceptibility to infection.[3] Not observed in our patient, however endocrine disorders such as diabetes, thyroid dysfunction, and hypogonadism may develop. Low IQ scores are more frequently reported, especially in congenital and early-onset cases.[3] Pneumonia, respiratory failure, and cardiac complications are among the most common causes of death in DM1 and they may shorten lifespan, as observed in the patient's father.[1,3,5,6,10]

Limitations

This case has several limitations. First, the ocular findings described in DM1 are well-known, however the present case is aimed to demonstrate early subtle changes that may be easily overlooked. Second, the exact CTG repeat number could not be determined because it was not reported in the test available. Lastly, fundus autofluorescence and fluorescein angiography, could not be performed and, the choroidal thickness could not be measured because the related devices were not available in our clinic. Although the choroid was partially visible on the available OCT images and seems to be in normal limits, its posterior boundary could not be clearly identified.

CONCLUSION

As a result, while there is no definitive cure for the disease, collaborative approach by cardiology, neurology, pulmonology, ophthalmology, and genetics departments is recommended. Regular ophthalmological examinations, cardiac screening, and early detection of systemic complications can improve quality of life and survival. Counselling and cooperation with family members are very important in order to reduce morbidity and delay mortality in these patients.

ETHICAL DECLARATIONS

Informed Consent

Written informed consent was obtained from the patient included in this report. Signed consent forms are retained by the authors and are available upon request.

Peer Review Process

This report underwent external peer review.

Conflict of Interest

The author declare no conflicts of interest.

Financial Disclosure

This case report did not receive any financial support.

Author Contributions

The author is solely responsible for the entirety of conception, execution, analysis, and writing of the manuscript.

REFERENCES

1. Hartman J, Patki T, Johnson NE. Diagnosis and management of myotonic dystrophy type 1. *JAMA*. 2024;331(14):1227-1228. doi:10.1001/jama.2024.2511
2. Ikeda KS, Iwabe-Marchese C, França Jr MC, Nucci A, de Carvalho KM. Myotonic dystrophy type 1: frequency of ophthalmologic findings. *Arq Neuropsiquiatr*. 2016;74(3):183-188. doi:10.1590/0004-282X20150218
3. Bird TD. Myotonic Dystrophy Type 1. University of Washington, Seattle, Seattle (WA); 1993.
4. Chahine M, Ginjupalli VKM, Jauvin D, Boutjdir M. Therapeutic strategies targeting the molecular pathogenesis of myotonic dystrophy type 1: current status and future directions. *Mol Diagn Ther*. 2026. doi:10.1007/s40291-026-00848-3
5. Turner C, Hilton-Jones D. The myotonic dystrophies: diagnosis and management. *J Neurol Neurosurg Psychiatry*. 2010;81(4):358-367. doi:10.1136/jnnp.2008.158261
6. Rahm L, Hale MA, Raaijmakers RHL, et al. Myotonic dystrophy type 1: clinical diversity, molecular insights and therapeutic perspectives. *Nat Rev Neurol*. 2025;21(11):623-641. doi:10.1038/s41582-025-01139-x
7. Abed E, D'Amico G, Rossi S, Perna A, Bianchi MLE, Silvestri G. Spectral domain optical coherence tomography findings in myotonic dystrophy. *Neuromuscular Disorders*. 2020;30(2):144-150. doi:10.1016/j.nmd.2019.11.012
8. Vasilijevic J, Peric S, Basta I, et al. Retinal vascular abnormalities in myotonic dystrophy assessed by optical coherence tomography angiography-cross-sectional study. *Eur J Ophthalmol*. 2025;35(1):262-268. doi:10.1177/11206721241247424
9. Akan O, Erden B. Optical coherence tomography findings in patients with myotonic dystrophy type 1. *Eur Arch Med Res*. 2021;37(3):178-182. doi:10.4274/eamr.galenos.2021.53315
10. Ginjupalli VKM, Reisqs JB, Cupelli M, Chahine M, Boutjdir M. Cardiac involvement in myotonic dystrophy type 1: mechanisms, clinical perspectives, and emerging therapeutic strategies. *Int J Mol Sci*. 2025;26(22):10992. doi:10.3390/ijms262210992

Archives of
Ophtalmological Research

Case Report

DOI: 10.51271/AOR-0051

Acute angle closure following repeated periocular *Botulinum* toxin injection for blepharospasm: a case report

Yaşar Ölmez*, Erdem Dursun
Department of Ophthalmology, Faculty of Medicine, Kırıkkale University, Kırıkkale, Turkiye

Cite this article: Ölmez Y, Dursun E. Acute angle closure following repeated periocular *Botulinum* toxin injection for blepharospasm: a case report. *Arch Ophthalmol Res.* 2026;3(2):31-33. doi:10.51271/AOR-0051

Received: 28/05/2026 ◆ **Accepted:** 29/06/2026 ◆ **Published:** 30/06/2026

ABSTRACT

Acute angle closure (AAC) is an ophthalmic emergency characterized by sudden elevation of intraocular pressure due to obstruction of aqueous humor outflow. Several systemic and topical medications, including *Botulinum* toxin, have been implicated in precipitating AAC in susceptible individuals. *Botulinum* toxin may induce mydriasis through inhibition of acetylcholine release at parasympathetic nerve terminals. We report the case of a 52-year-old woman who developed *Botulinum* toxin-associated AAC following repeated periocular *Botulinum* toxin injections for blepharospasm. The patient presented with ocular pain, redness, and blurred vision in the right eye three days after injection. Ophthalmic examination revealed elevated intraocular pressure, corneal edema, shallow anterior chambers, and closed iridocorneal angles on gonioscopy. Additional examination demonstrated hyperopia in the fellow eye, bilateral occludable angles, iris bombe configuration, and relative mid-dilation of the affected pupil, suggesting a pupillary block mechanism. After initial medical treatment, bilateral neodymium (Nd) laser peripheral iridotomy was successfully performed, resulting in normalization of intraocular pressure without recurrence during approximately 12 months of follow-up. Although rare, *Botulinum* toxin-associated AAC should be considered in patients with occludable angles and other anatomical risk factors. Careful anterior chamber angle assessment before periocular *Botulinum* toxin administration may help identify patients at risk and prevent vision-threatening complications.

Keywords: Acute angle closure, *Botulinum* toxin, blepharospasm, laser peripheral iridotomy

INTRODUCTION

Glaucoma is one of the leading causes of irreversible blindness worldwide.[1] Among glaucoma subtypes, primary angle-closure glaucoma is associated with a particularly high risk of severe visual loss if left untreated. Acute angle closure (AAC) develops when obstruction of the trabecular meshwork by the peripheral iris impairs aqueous humor drainage, resulting in a sudden increase in intraocular pressure.

Several medications are known to precipitate AAC, especially in predisposed individuals with shallow anterior chambers, occludable iridocorneal angles, hyperopia, or increased lens thickness. Commonly implicated agents include anticholinergics, adrenergic drugs, antidepressants, antihistamines, anticonvulsants, and *Botulinum* toxin preparations.[2,8-10] Recent reviews have emphasized that drug-induced angle closure remains an underrecognized but potentially vision-threatening clinical entity requiring early recognition and management.[8-10]

Botulinum toxin has been increasingly used for both therapeutic and cosmetic indications. It acts by inhibiting acetylcholine release at cholinergic nerve terminals and may induce pupillary dilation through parasympathetic blockade. This pharmacologic effect may trigger angle closure in susceptible individuals.

Herein, we report a rare case of *Botulinum* toxin-associated AAC developing after repeated periocular *Botulinum* toxin injections administered for blepharospasm.

CASE

A 52-year-old woman was referred to the ophthalmology clinic with complaints of severe pain, redness, and blurred vision in the right eye. Her medical history was otherwise unremarkable, and she had no known family history of glaucoma.

Best-corrected visual acuity was 0.1 in the right eye and 0.8 in the left eye. Intraocular pressure measured by Goldmann applanation tonometry was 38 mmHg in the right eye and 18 mmHg in the left eye. Slit-lamp examination revealed corneal edema and a markedly shallow anterior chamber in the right eye. The anterior chamber of the left eye was also shallow. Fundus examination of the right eye could not be

***Corresponding Author:** Yaşar Ölmez, yolmez01@gmail.com

This work is licensed under a Creative Commons Attribution 4.0 International License.

performed because of corneal edema, whereas the left fundus examination was normal.

The patient was hospitalized and treated with oral acetazolamide, intravenous mannitol infusion, topical pilocarpine, brinzolamide/timolol, apraclonidine, and travoprost. One day later, her symptoms had markedly improved, and intraocular pressure decreased to 9 mmHg in the right eye and 11 mmHg in the left eye.

At one-week follow-up, intraocular pressures remained within normal limits without significant symptoms. Because intraocular pressure responded rapidly to medical treatment and no history of recent *Botulinum* toxin injection was obtained during the initial evaluation, laser peripheral iridotomy was not performed at that time. However, one week later, the patient returned with recurrent pain and redness in the right eye. Visual acuity was 0.7 in the right eye and 0.9 in the left eye. Intraocular pressure was 32 mmHg in the right eye and 14 mmHg in the left eye. Slit-lamp examination demonstrated shallow anterior chambers bilaterally, and the right pupil appeared relatively dilated. Gonioscopy revealed occludable angles with no visible angle structures (Shaffer grade 0 could not be formally documented because grading had not been recorded during the acute examination), more pronounced in the right eye.

Detailed anamnesis revealed that the patient had been receiving periocular *Botulinum* toxin injections every three months for blepharospasm for approximately seven years. The last injection had been administered three days before symptom onset. According to the patient's history, Dysport® (abobotulinumtoxinA) had been administered around the right eye at a private aesthetic center. The exact dose and injection pattern could not be determined because the treatment records were unavailable despite attempts to obtain additional information from the treating center. The patient reported that the procedure had been performed by a general practitioner.

The right eye could not be refracted because of corneal edema during the acute attack. The fellow eye demonstrated +3.50 diopters of hyperopia. Both eyes were phakic without clinically significant cataract. The presence of hyperopia, occludable angles, iris bombe configuration, and relative mid-dilation of the affected pupil suggested a pupillary block mechanism and anatomical predisposition to angle closure. Shaffer gonioscopic grading, axial length measurements, anterior chamber depth measurements, and pre-iridotomy anterior segment optical coherence tomography (AS-OCT) images were not available because these examinations were not performed during the acute presentation.

Considering the temporal relationship between injection and symptoms, *Botulinum* toxin-associated AAC was diagnosed. Bilateral Nd laser peripheral iridotomy was subsequently performed (**Figure**).

One hour after iridotomy, intraocular pressure was 20 mmHg in the right eye and 18 mmHg in the left eye. At one-week follow-up, intraocular pressure had decreased to 13 mmHg in the right eye and 15 mmHg in the left eye without additional medication. The patient was followed for approximately 12 months after bilateral Nd laser peripheral iridotomy. At the final follow-up visit, best-corrected visual acuity was 0.8 in the affected eye and intraocular pressure was 13 mmHg without medication. No recurrence of AAC was observed during follow-up.

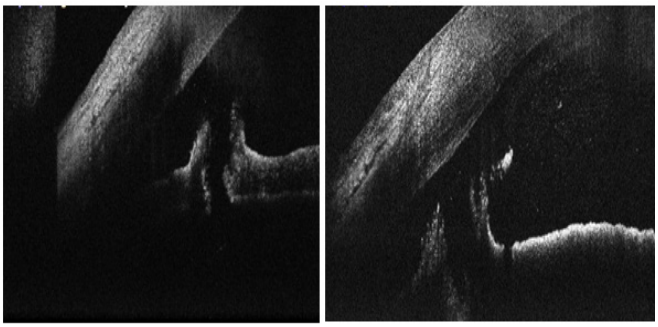

Figure. Anterior segment optical coherence tomography images obtained after bilateral Nd laser peripheral iridotomy demonstrating patent iridotomies and widening of the iridocorneal angle. Pre-iridotomy anterior segment OCT images were unavailable because imaging was not performed during the acute attack

Nd: Neodymium, OCT: Optical coherence tomography

DISCUSSION

Botulinum toxin was first introduced into ophthalmic practice by Alan B. Scott in 1980 for the treatment of strabismus.[3] Subsequently, it became widely used in the management of blepharospasm, hemifacial spasm, and cosmetic facial procedures. Although generally considered safe, periocular *Botulinum* toxin injections may lead to ocular complications including ptosis, diplopia, dry eye, and rarely AAC.[4]

Only a limited number of cases describing AAC following periocular *Botulinum* toxin injection have been reported in the literature.[5] Corridan et al.[4] reported AAC developing three days after *Botulinum* toxin injection for blepharospasm, whereas Zheng and Azar[5] described a similar event following periorbital *Botulinum* toxin administration. Similar to these reports, our patient developed symptoms three days after injection and achieved successful long-term control following bilateral Nd laser peripheral iridotomy.

The exact mechanism underlying *Botulinum* toxin-associated AAC remains unclear. The most widely accepted hypothesis suggests diffusion of the toxin toward the ciliary ganglion, leading to parasympathetic blockade of the pupillary sphincter muscle and subsequent mydriasis. In anatomically predisposed eyes with occludable angles, pupillary dilation may precipitate pupillary block and angle closure.[6,7]

Experimental studies have demonstrated that periocular or retrobulbar *Botulinum* toxin administration may induce mydriasis through autonomic effects on pupillary innervation.[6] In addition, toxin diffusion through fascial planes, adjacent tissues, and orbital fat has been proposed as a mechanism responsible for unintended ocular side effects.[7]

Our patient had several established anatomical risk factors for angle closure, including hyperopia (+3.50 diopters in the fellow eye), phakic status, occludable angles, iris bombe configuration, and a relatively mid-dilated pupil during the acute episode. These findings suggest a pre-existing predisposition to pupillary block and angle closure. The presence of iris bombe and relative mydriasis further supports a pupillary block mechanism as the most likely explanation for the acute attack.

Laser peripheral iridotomy was not performed after the initial attack because intraocular pressure responded rapidly to medical treatment and a recent history of *Botulinum* toxin

injection was not identified during the initial evaluation. The association became apparent only after recurrence and detailed reassessment of the patient's history, which prompted definitive treatment with bilateral laser peripheral iridotomy.

Recent literature has increasingly focused on medication-induced angle closure and the importance of identifying susceptible individuals before exposure to precipitating agents. Contemporary reviews have highlighted that pharmacologically induced mydriasis remains one of the major mechanisms underlying drug-associated angle closure, particularly in patients with occludable angles.[8-10] Furthermore, updated ophthalmology guidelines emphasize the importance of gonioscopic evaluation and patient education in preventing irreversible visual loss associated with acute angle-closure attacks.[10]

Although a causal relationship cannot be definitively established from a single case report, the close temporal association between Dysport® injection and symptom onset, together with the absence of recurrent attacks during approximately 12 months of follow-up after laser peripheral iridotomy, suggests that *Botulinum* toxin may have acted as a triggering factor in a patient with pre-existing anatomical susceptibility. Therefore, the term "*Botulinum* toxin-associated acute angle closure" may be more appropriate than "*Botulinum* toxin-induced AAC."

With the increasing use of *Botulinum* toxin for both therapeutic and cosmetic indications worldwide, awareness of rare ophthalmic complications has become increasingly important. Recent evidence suggests that drug-induced angle closure is frequently overlooked during preprocedural evaluation despite being potentially preventable in high-risk patients.[8-10] Comprehensive ophthalmologic assessment, including gonioscopy or anterior segment imaging, may help identify susceptible individuals before treatment. In selected patients with occludable angles, prophylactic laser peripheral iridotomy may reduce the risk of AAC attacks.

This case report has several limitations. The exact dose and injection pattern of *Botulinum* toxin could not be confirmed because the treatment records from the outside treatment center were unavailable despite attempts to obtain additional information. Furthermore, Shaffer gonioscopic grading, axial length measurements, anterior chamber depth measurements, and pre-iridotomy AS-OCT images were unavailable because these examinations were not performed during the acute presentation. Despite these limitations, the close temporal relationship between periocular *Botulinum* toxin injection and symptom onset, together with the presence of hyperopia, occludable angles, iris bombe configuration, and the favorable response to bilateral laser peripheral iridotomy, supports a probable association between periocular *Botulinum* toxin injection and AAC.

CONCLUSION

Periocular *Botulinum* toxin injection may rarely trigger AAC in susceptible individuals with occludable angles and other anatomical risk factors for pupillary block. Ophthalmologic assessment before treatment, particularly in middle-aged and elderly patients, may help prevent this potentially sight-threatening complication. Careful gonioscopic evaluation may help identify patients at increased risk before periocular *Botulinum* toxin administration. In selected high-risk patients, prophylactic laser peripheral iridotomy may be considered on an individual basis. Clinicians performing periocular *Botulinum* toxin injections should be aware of the symptoms of AAC and promptly refer affected patients for ophthalmologic evaluation.

ETHICAL DECLARATIONS

Informed Consent

Written informed consent was obtained from the patient included in this report. Signed consent forms are retained by the authors and are available upon request.

Peer Review Process

This report underwent external peer review.

Conflict of Interest

The authors declare no conflicts of interest.

Financial Disclosure

This case report did not receive any financial support.

Author Contributions

Concept: YO; Design: YO; Control: YO, ED; Resources: YO, ED; Materials: YO; Data Collection and/or Processing: YO; Analysis and/or Interpretation: YO, ED; Literature Review: YO, ED; Writing the Article: YO; Critical Review: YO.

REFERENCES

1. Quigley HA, Broman AT. The number of people with glaucoma worldwide in 2010 and 2020. *Br J Ophthalmol.* 2006;90(3):262-267. doi:10.1136/bjo.2005.081224
2. Lai JSM, Gangwani RA. Medication-induced acute angle closure attack. *Hong Kong Med J.* 2012;18(2):139-145.
3. Scott AB. *Botulinum* toxin injection into extraocular muscles as an alternative to strabismus surgery. *Ophthalmology.* 1980;87(10):1044-1049. doi:10.1016/S0161-6420(80)35127-0
4. Corridan P, Nightingale S, Mashoudi N, Williams AC. Acute angle-closure glaucoma following *Botulinum* toxin injection for blepharospasm. *Br J Ophthalmol.* 1990;74(5):309-310. doi:10.1136/bjo.74.5.309
5. Zheng L, Azar DT. Angle-closure glaucoma following periorbital *Botulinum* toxin injection. *Clin Exp Ophthalmol.* 2014;42(7):690-693. doi:10.1111/ceo.12328
6. Levy Y, Kremer I, Shavit S, Korczyn AD. The pupillary effects of retrobulbar injection of *Botulinum* toxin A in albino rats. *Invest Ophthalmol Vis Sci.* 1991;32(1):122-125.
7. Lim EC, Seet RC. *Botulinum* toxin: description of injection techniques and examination of controversies surrounding toxin diffusion. *Acta Neurol Scand.* 2008;117(2):73-84. doi:10.1111/j.1600-0404.2007.00966.x
8. Yang MC, Lin KY. Drug-induced acute angle-closure glaucoma: a review. *J Curr Glaucoma Pract.* 2019;13(3):104-109. doi:10.5005/jp-journals-10028-1266
9. Jain NS, Ruan CW, Dhanji SR, Symes RJ. Psychotropic drug-induced glaucoma: a practical guide to diagnosis and management. *CNS Drugs.* 2021;35(3):283-297. doi:10.1007/s40263-021-00807-2
10. O'Ryan Araneda FE, Estrin MA. Drug-induced acute-stage narrow-angle glaucoma: a review of the literature. *Interam J Health Sci.* 2024;5(2):1-12. doi:10.59471/ijhsc2025269

Archives of
Ophtalmological Research

Case Report

DOI: 10.51271/AOR-0052

Co-existence of multiple sclerosis and vitiligo in a patient with epithelial map-dot-fingerprint dystrophy

Serhat Eker*[1], Banu Bozkurt[1], Hakan Ekmekçi[2], Fettah Eren[2]
[1]Department of Ophthalmology, Faculty of Medicine, Selçuk University, Konya, Turkiye
[2]Department of Neurology, Faculty of Medicine, Selçuk University, Konya, Turkiye

Cite this article: Eker S, Bozkurt B, Ekmekçi H, Eren F. Co-existence of multiple sclerosis and vitiligo in a patient with epithelial map-dot-fingerprint dystrophy. *Arch Ophthalmol Res.* 2026;3(2):34-37. doi:10.51271/AOR-0052

Received: 28/05/2026 ◆ **Accepted:** 29/06/2026 ◆ **Published:** 30/06/2026

ABSTRACT

Multiple sclerosis is a chronic demyelinating central nervous system disease that manifests itself with muscle weakness, sensory disturbances and numbness in the extremities, impaired balance, gait, speech, blurred vision and diplopia seen in attacks. A 41-year-old female patient referred to us with the sudden complaints of blurred vision and diplopia in the right gaze. She had been following up with the diagnosis of recurrent corneal erosions and epithelial basement membrane dystrophy in the ophthalmology department for the last three years. In cranial magnetic resonance imaging, there were hyperintense lesions in the bilateral periventricular white matter, which was remarkable in the right hemisphere in T2W scan. She also had acrocephalic vitiligo and multinodular goiter for years. HLA-A2, DRB1*0407, DRB1*1301, DQB1*0301, DQB1*0603 haplotypes were detected. Both autoimmunity and genetic factors may play a role in the co-existence of multiple sclerosis and vitiligo.
Keywords: Autoimmunity, corneal dystrophy, epithelial basement membrane, HLA antigens, multiple sclerosis, vitiligo

INTRODUCTION

Multiple sclerosis (MS) is a chronic demyelinating central nervous system (CNS) disease that manifests itself with muscle weakness, sensory disturbances and numbness in the extremities, impaired balance, gait, speech, blurred vision and diplopia seen in attacks.[1] Ophthalmic involvement includes optic neuritis, internuclear ophthalmoplegia, trigeminal neuralgia, diplopia and uveitis.[2] In the literature, there are some studies showing higher prevalence of autoimmune diseases such as Graves' disease, rheumatoid arthritis, vitiligo and type 1 insulin-dependent diabetes mellitus in MS patients.[3-5]

Herein, we report a female patient who had been followed up with the diagnosis of epithelial basement membrane dystrophy (EBMD) and acrocephalic vitiligo for years and was diagnosed to have MS after a sudden complaint of diplopia. Although studies in the literature have shown a relationship between MS and autoimmune diseases such as Graves' disease, rheumatoid arthritis, hypothyroidism, vitiligo, and type 1 diabetes,[3-6] there are no studies that determine whether the co-existence of MS and EBMD is associated or coincidental. In this context, our case is the first study in literature to demonstrate this co-occurrence.

CASE

A 41-year-old female patient referred to us with the sudden complaints of blurred vision and diplopia in the right gaze. She had been followed up with the diagnosis of recurrent corneal erosions and EBMD in the ophthalmology department for the last three years.

The best corrected visual acuity was 20/20 in the right eye and 20/25 in the left eye. Comma and dot-like hyperreflective opacities and corneal punctate epitheliopathy were observed in biomicroscopic examination of the right eye (**Figure 1A, B**). In vivo laser confocal microscopic findings of the patient revealed showing distorted epithelium, multiple hyperreflective dots and thickened basement membrane (**Figure 1C, D**). Pupils were isocoric and there was no relative afferent pupillary defect. There was a mild abduction deficiency in the right eye. The Ishihara test showed no impairment in color vision. The optic discs of both eyes were normal.

Neurological examination revealed no other abnormalities. Visual evoked potential (VEP) test results were normal. In cranial magnetic resonance imaging, there were hyperintense lesions in the bilateral periventricular white matter, which was remarkable on the right hemisphere in T2W scan.

***Corresponding Author:** Serhat Eker, drserhateker@gmail.com

This work is licensed under a Creative Commons Attribution 4.0 International License.

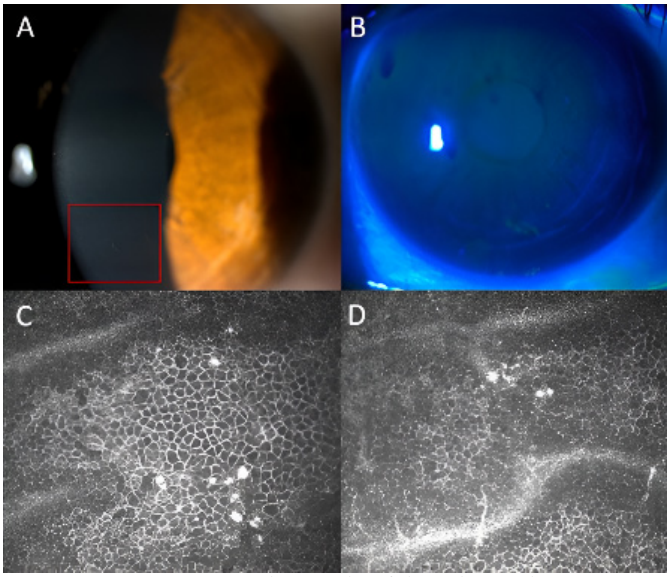

Figure 1. Anterior segment photographs of the right eye showing comma and dot-like hyperreflective opacities (A) and corneal punctate epitheliopathy (B) in the inferior paracentral cornea. In vivo confocal microscopy images showing distorted epithelium, multiple hyperreflective dots and thickened basement membrane (C, D)

Furthermore, periventricular plaques and juxtacortical hyperintense lesion draw attention in the coronal T2 flair sequence (Figure 2). According to 2010 McDonald criteria, the patient was diagnosed with MS considering current neurological findings and neuro imaging.[7] Spinal magnetic resonance imaging scans revealed osteophytic spurs and degenerative changes in the cervical and lumbar vertebrae. No additional findings of demyelinating disease were observed. She also had acrocephalic vitiligo and multinodular goiter for years. The vitiligo spots were localized on the face, hands, and feet (Figure 3). The patient had no thyroid hormone-related symptoms. Furthermore, TSH, free T3, and free T4 laboratory results were within normal limits. No positive thyroid autoantibody result was observed.

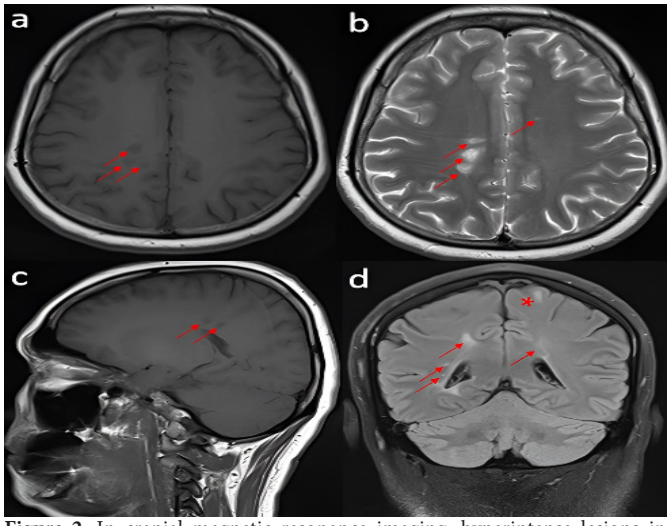

Figure 2. In cranial magnetic resonance imaging, hyperintense lesions in bilateral periventricular white matter, more prominent on the right in T1W axial (A), T2W axial (B), and T1W sagittal (C) sections (red arrows). In addition to periventricular plaques, juxtacortical hyperintense lesion draws attention (asterisk) in the coronal T2 flair sequence (D)

Complete blood count, blood electrolytes, renal and liver function tests, rheumatoid factor, erythrocyte sedimentation rate and serum C-reactive protein levels were normal. Anti-nuclear antibody profile and serology of viral hepatitis, brucella and syphilis were negative. Body temperature and other vital signs were normal. Cerebrospinal fluid (CSF) sample analysis with isoelectric focusing method revealed oligoclonal band; however, no oligoclonal band was detected in serum sample. No bacteria were detected in the CSF examination and microbial culture was negative.

Figure 3. Depigmented macular lesions are seen in the patient with a diagnosis of vitiligo

The patient was diagnosed with MS and IV pulse methylprednisolone (1000 mg) was given for five days. After five days of intravenous steroids, oral prednisone tapering was planned. The patient was discharged with dimethyl fumarate treatment to prevent the recurrence of MS attacks in the long-term. Diplopia and blurred vision improved after three weeks.

The patient was also screened for human leukocyte antigen (HLA) A-B-C and DQ-DR alleles for any other association or risks of autoimmune diseases. HLA molecular analysis was performed by PCR method. Positive results of HLA-A201, HLA-B4006, HLA-B5101, HLA-C0401, HLA-C1502, DRB1*0407, DRB1*1301, DQB1*0301, DQB1*0603 were observed. Written informed consent was obtained and included.

DISCUSSION

In the current study, a female patient who was followed up for recurrent corneal erosions related to EBMD was diagnosed as MS after acute diplopia. EBMD is the most common corneal dystrophy, where basement membrane thickens and extra sheets of basement membrane extend into the corneal epithelium.[8] The characteristic slit-lamp findings are "maps" which appear as amorphous or geographic, sharply demarcated clear zones within light grayish areas, "dots" as small, irregular putty-like grayish white opacities and "fingerprints" as small clusters of curved, parallel lines.[9] Although, most patients do not seem to have a family history, certain point mutations in the TGFBI gene on chromosome five may be responsible for some of the cases. Therefore, EBMD is supposed to be degenerative in nature rather than hereditary.[10] The coexistence of MS and EBMD in our patient seems to be coincidental. In the literature, there is no report showing an association between EBMD and MS and no systemic abnormalities have been documented in patients with EBMD.[10]

She had also vitiligo and multinodular goiter which might support the hypothesis that autoimmunity or certain HLA alleles might play role in the co-association of these diseases. MS can develop before or after the emergence of autoimmune diseases. In an observational study conducted by Sahraian et al.,[3] rheumatoid arthritis (12%), psoriasis (12%), eczema (12%) and autoimmune hepatitis (8%) are the most seen concomitant disorders in MS patients. In 62% of the patients, autoimmune diseases were diagnosed before, while in 16% of cases MS appeared initially. MS and autoimmune disease onset occurred together within approximately one year in the rest of the subjects. Interestingly, disability progression develops more slowly in MS patients with concurrent autoimmune disease. This was explained by the thesis that accompanying autoimmune disease might increase the body's tolerance to autoantigens.[3] Barcellos et al.[4] conducted a study of 386 patients with MS and 1107 their first-degree relatives for history of other autoimmune disorders. At least one autoimmune disease was seen in 26% of the index cases. Hashimoto thyroiditis (10%), psoriasis (6%), inflammatory bowel disease (3%), and rheumatoid arthritis (2%) were the most common ones. In the meta-analysis of Dobson and Giovannoni,[5] the overall additional risk for autoimmune diseases was calculated in people with MS and their first-degree relatives. Thyroid disease has been shown to increase in both MS patients and their relatives.[5] On the other hand, in the cohort study of Roshanisefat et al.,[11] parents of MS patients did not show increased risk for immune-mediated disease. Among MS patients, an elevated risk of other autoimmune diseases was noted; however, surveillance bias was thought to cause the difference.

Vitiligo, characterized by well-defined depigmented macules and patches, is seen in 1-2% of the population. Autoimmune destruction of melanocytes is one of the most suggested hypotheses in etiopathogenesis. Vitiligo has been associated with many autoimmune diseases and the prevalence of vitiligo was reported to be higher in MS patients compared to the controls.[12] Similarly, Gill et al.[13] reported that MS disease was more common in vitiligo patients. In the study by Hadi et al.,[14] data of 1487 vitiligo cases retrospectively analyzed during a 10-year period to investigate the associated autoimmune disorders. 15.3% of overall vitiligo patients had statistically significant comorbid autoimmune conditions. Prevalence of hypothyroidism, MS, rheumatoid arthritis, systemic lupus erythematosus, idiopathic thrombocytopenic purpura, seronegative arthritis, myasthenia gravis, inflammatory bowel disease, pernicious anemia, and lymphoma was significantly increased compared to data of the general population. Hypothyroidism (7.6%) and rheumatoid arthritis (1.6%) are the most common. However, this comprehensive study did not demonstrate any cases indicating a relationship between EBMD and vitiligo, or between EBMD and MS. In addition, in the meta-analysis by Shen and co-workers,[15] including six cohort studies with 12,930 subjects, no significant relationship was found between MS and vitiligo. Unless further genetic investigations confirm a possible autoimmune association between MS, vitiligo, and EBMD, it seems likely to continue to be considered coincidentally.

Genes of the major histocompatibility complex (MHC), and especially the class II genes are associated with many inflammatory diseases including MS. HLADRB1*15:01, HLA-DRB1, HLA-DQB1, HLA-DRA were reported in MS patients. DRB1*1501-DQB1*0602 haplotype was shown to be more common in Iranian and Turkish populations.[16] MHC class I (HLA-A) and MHC class II (HLA-DRB1/-DQA1) genes were shown to be related also with autoimmune vitiligo. In the meta-analysis of 11 studies, HLA-A2 was found as the most important one in the development of vitiligo.[17] HLA-DRB1 was found to be associated both with MS and vitiligo. In our case, HLA-A2, DRB1*0407, DRB1*1301, DQB1*0301, DQB1*0603 haplotypes were detected.

CONCLUSION

As a result, autoimmunity and certain HLA haplotypes seem to play a role in the co-existence of acrocephalic vitiligo, multinodular goiter and MS in our patient. A single observational case study cannot explain causal or pathogenetic relationships in this regard. Comprehensive genetic studies are needed to investigate the association of EBMD with other autoimmune diseases.

ETHICAL DECLARATIONS

Informed Consent

Written informed consent was obtained from the patient included in this report. Signed consent forms are retained by the authors and are available upon request.

Peer Review Process

This report underwent external peer review.

Conflict of Interest

The authors declare no conflicts of interest.

Financial Disclosure

This case report did not receive any financial support.

Author Contributions

Concept: SE, BB; Design: SE, BB, HE, FE; Control: SE, BB, HE; Resources: SE, BB, FE; Materials: BB, HE, FE; Data Collection and/or Processing: SE, BB, HE, FE; Analysis and/or Interpretation: SE, BB; Literature Review: SE, FE; Writing the Article: SE, BB; Critical Review: SE, BB, HE, FE.

REFERENCES

1. Dobson R, Giovannoni G. Multiple sclerosis: a review. *Eur J Neurol.* 2019;26(1):27-40. doi:10.1111/ene.13819
2. Lublin FD, Reingold SC, Cohen JA, et al. Defining the clinical course of multiple sclerosis: the 2013 revisions. *Neurology.* 2014;83(3):278-286. doi:10.1212/WNL.0000000000000560
3. Sahraian MA, Owji M, Naser Moghadasi A. Concomitant multiple sclerosis and another autoimmune disease: does the clinical course change? *Clin Neurol Neurosurg.* 2016;150:92-95. doi:10.1016/j.clineuro.2016.08.027
4. Barcellos LF, Kamdar BB, Ramsay PP, et al. Clustering of autoimmune diseases in families with a high risk of multiple sclerosis: a descriptive study. *Lancet Neurol.* 2006;5(11):924-931. doi:10.1016/S1474-4422(06)70581-5
5. Dobson R, Giovannoni G. Autoimmune disease in people with multiple sclerosis and their relatives: a systematic review and meta-analysis. *J Neurol.* 2013;260(5):1272-1285. doi:10.1007/s00415-012-6790-1
6. Cojocaru M, Cojocaru IM, Silosi I. Multiple autoimmune syndrome. *Maedica (Bucur).* 2010;5(2):132-134.
7. Thompson AJ, Banwell BL, Barkhof F, et al. Diagnosis of multiple sclerosis: 2017 revisions of the McDonald criteria. *Lancet Neurol.* 2018;17(2):162-173. doi:10.1016/S1474-4422(17)30470-2
8. Brown N, Bron A. Recurrent erosion of the cornea. *Br J Ophthalmol.* 1976;60(2):84-96. doi:10.1136/bjo.60.2.84

9. Bron AJ, Tripathi RC. Cystic disorders of the corneal epithelium. I. Clinical aspects. *Br J Ophthalmol.* 1973;57(6):361-375. doi:10.1136/bjo.57.6.361
10. Weiss JS, Møller HU, Aldave AJ, et al. IC3D classification of corneal dystrophies-edition 2. *Cornea.* 2015;34(2):117-159. doi:10.1097/ICO.0000000000000307
11. Roshanisefat H, Bahmanyar S, Hillert J, Olsson T, Montgomery S. Shared genetic factors may not explain the raised risk of comorbid inflammatory diseases in multiple sclerosis. *Mult Scler.* 2012;18(10):1430-1436. doi:10.1177/1352458512438234
12. Deretzi G, Kountouras J, Polyzos SA, et al. Polyautoimmunity in a Greek cohort of multiple sclerosis. *Acta Neurol Scand.* 2015;131(4):225-230. doi:10.1111/ane.12331
13. Gill L, Zarbo A, Isedeh P, Jacobsen G, Lim HW, Hamzavi I. Comorbid autoimmune diseases in patients with vitiligo: a cross-sectional study. *J Am Acad Dermatol.* 2016;74(2):295-302. doi:10.1016/j.jaad.2015.08.063
14. Hadi A, Wang JF, Uppal P, Penn LA, Elbuluk N. Comorbid diseases of vitiligo: a 10-year cross-sectional retrospective study of an urban US population. *J Am Acad Dermatol.* 2020;82(3):628-633. doi:10.1016/j.jaad.2019.08.063
15. Shen MH, Ng CY, Chang KH, Chi CC. Association of multiple sclerosis with vitiligo: a systematic review and meta-analysis. *Sci Rep.* 2020;10(1):17792. doi:10.1038/s41598-020-74945-3
16. Maghbooli Z, Sahraian MA, Naser Moghadasi A. Multiple sclerosis and human leukocyte antigen genotypes: focus on the Middle East and North Africa region. *Mult Scler J Exp Transl Clin.* 2020;6(1):2055217319881775. doi:10.1177/2055217319881775
17. Liu JB, Li M, Chen H, et al. Association of vitiligo with HLA-A2: a meta-analysis. *J Eur Acad Dermatol Venereol.* 2007;21(2):205-213. doi:10.1111/j.1468-3083.2006.01953.x

Archives of
Ophtalmological Research

Letter to the Editor

DOI: 10.51271/AOR-0053

Comments on "Impact of phacoemulsification on choroidal and ganglion cell complex thickness assessed by spectral-domain optical coherence tomography"

İlter Güçlü
Department of Ophthalmology, Kırşehir Training and Research Hospital, Kırşehir, Turkiye

Cite this article: Güçlü İ. Comments on "Impact of phacoemulsification on choroidal and ganglion cell complex thickness assessed by spectral-domain optical coherence tomography". *Arch Ophthalmol Res.* 2026;3(2):38-39. doi:10.51271/AOR-0053

Received: 08/03/2026 ◆ **Accepted:** 23/04/2026 ◆ **Published:** 30/06/2026

Keywords: Ganglion cell complex thickness, phacoemulsification, subfoveal choroidal thickness

Dear Editor,

We read with great interest the article by Demir and Çelik[1] evaluating the effect of uncomplicated phacoemulsification on subfoveal choroidal thickness, ganglion cell complex thickness (GCCT), central macular thickness, and peripapillary retinal nerve fiber layer thickness. The authors should be commended for addressing a clinically relevant question, particularly because postoperative optical coherence tomography (OCT) interpretation may influence the follow-up of patients with glaucoma and retinal or choroidal disorders.

The finding that all evaluated OCT parameters increased at postoperative month 1 is noteworthy and supports the concept that even uneventful cataract surgery may induce transient posterior segment alterations. We believe this message is important for clinicians, especially when establishing new postoperative baselines.

However, a few points deserve clarification. First, the reported ganglion cell complex thickness values appear inconsistent across sections of the manuscript. In the abstract and Table 3, GCCT is reported as increasing from 83.2±4.4 µm to 91.4±6.1 µm, whereas in the Results section the increase is given as 85.0±4.4 µm to 89.2±5.3 µm. Because GCCT is one of the main outcome measures, clarification of the correct values would interpretability of the study.

Second, the OCT acquisition protocol appears contradictory. The Methods state that scans were obtained without dilation to minimize the effects of mydriasis, yet later the analyzed measurements are described as having been obtained after pharmacologic pupil dilation. Although previous OCT studies have generally reported no significant differences in GCC measurements before and after dilation, image quality and signal strength are known to influence OCT measurement repeatability and thickness estimates.[2,3] Therefore, clarification of the actual imaging protocol and image-quality criteria would improve the methodological transparency and comparability of the study.

Overall, this study contributes valuable information regarding early postoperative OCT changes after phacoemulsification. Clarification of the issues above would further enhance its methodological transparency and clinical impact.

Sincerely,

ETHICAL DECLARATIONS

Peer Review Process

This letter was externally peer-reviewed.

Conflict of Interest

The author declare no conflicts of interest.

Financial Disclosure

No financial support was received for the preparation or publication of this letter.

Author Contributions

The author is solely responsible for the entirety of conception, execution, analysis, and writing of the manuscript.

REFERENCES

1. Demir K, Çelik E. Impact of phacoemulsification on choroidal and ganglion cell complex thickness assessed by spectraldomain optical coherence tomography. *Arch Ophthalmol Res.* 2025;2(4):58-62. doi:10.51271/AOR-0038
2. Massa GC, Vidotti VG, Cremasco F, Lupinacci APC, Costa VP. Influence of pupil dilation on retinal nerve fibre layer measurements with spectral domain OCT. *Eye (Lond).* 2010;24(9):1498-1502. doi:10.1038/eye.2010.72
3. Zhang X, Iverson SM, Tan O, Huang D. Effect of signal intensity on measurement of ganglion cell complex and retinal nerve fiber layer scans in Fourier-domain optical coherence tomography. *Transl Vis Sci Technol.* 2015;4(5):7. doi:10.1167/tvst.4.5.7

Corresponding Author: İlter Güçlü, ilterguclu@gmail.com

This work is licensed under a Creative Commons Attribution 4.0 International License.

Reply to the Letter to the Editor "Impact of phacoemulsification on choroidal and ganglion cell complex thickness assessed by spectral-domain optical coherence tomography"

Kadriye Demir[1], Erkan Çelik[2]

[1]Department of Ophthalmology, Faculty of Medicine, Sakarya University, Sakarya, Turkiye
[2]Department of Ophthalmology, Sakarya Dünyagöz Hospital, Sakarya, Turkiye

Dear Editor,

We thank the authors of the Letter to the Editor for their careful reading of our article and for their constructive comments. We appreciate their interest in our study and their emphasis on the clinical relevance of postoperative optical coherence tomography (OCT) interpretation.

First, we acknowledge the inconsistency in the reported ganglion cell complex thickness (GCCT) values. In the published article, the Abstract and Table 3 reported different GCCT values from those presented in the Results section. The correct values are those reported in the Results section: GCCT increased from 85.0±4.4 µm preoperatively to 89.2±5.3 µm at postoperative month 1. This discrepancy was due to a typographical error, and we appreciate the opportunity to clarify it.

Second, we agree that the description of the OCT acquisition protocol was inconsistent. Although one sentence in the Methods section stated that the analyzed measurements were obtained after pharmacologic pupil dilation, the actual study protocol involved OCT acquisition without pharmacologic dilation, performed between 2:00 and 4:00 p.m. to minimize the effects of mydriasis and diurnal variation. We confirm that all OCT measurements were obtained without dilation. In addition, only scans with signal strength of 6 or greater were included to ensure measurement reliability.

These clarifications do not change the main conclusion of our study: uncomplicated phacoemulsification was associated with significant increases in subfoveal choroidal thickness, GCCT, central macular thickness, and peripapillary retinal nerve fiber layer thickness at postoperative month 1. We agree that awareness of these early postoperative changes is important when establishing new OCT baselines in clinical practice.

We thank the correspondents once again for their valuable comments and for the opportunity to improve the clarity of our work.

Sincerely,
Kadriye Demir, MD
on behalf of all authors